

# NEWS FOR FARRIERS

## NEW PRODUCTS NOW SHIPPING TO FPD DEALERS

Visit [farrierproducts.com/locations](http://farrierproducts.com/locations) to find FPD dealers carrying these exciting new products.

### New Hoofjack Pastern Cradle



The Hoofjack Pastern Cradle is designed to give even more support and comfort. The double cradle/strap allows the leg to lie in a more stable position, providing greater comfort to the horse while allowing the farrier to work more easily. The Pastern Cradle fits securely into all Hoofjack bases.



### New Save Edge Wide Drive-On Rasp Handles

The Save Edge Wide Drive-On Rasp Handle is a great replacement option for the discontinued Chameleon MAX Green Rasp Handle. These handles fit wide format rasps, including the Save Edge Dark Horse and White Horse, and the Diamond Max Glide.

The Save Edge Wide Drive-On Rasp Handle is available in Green and Purple.



### New Kerckhaert Pride 7/8", size 11.5 Slider

This is a Kerckhaert high quality steel shoe designed as an option for reining and roping horses, especially younger horses. The high quality steel provides durability and strength.



- C45 steel for longer wear
- Heel finish is superior
- Good shape
- Clean punching allows for numerous nail options – the most popular are 4-1/2 race and 5 special

## SAVE THE DATES: FPD Sponsored Clinics and AFA Convention

The **Farrier Hub 2nd Annual Spring Clinic** will be held March 7, 2026 in Cave Creek, Arizona, with Clinician Austin Edens, CJF. For more information, visit [www.farrierproducts.com/events](http://www.farrierproducts.com/events).

The **Ken Davis & Sons Farrier Clinic** will be held March 14, 2026 in Richwood, Ohio, with Clinicians Bobby Menker and Steve Stanley. For more information, visit [www.farrierproducts.com/events](http://www.farrierproducts.com/events).

The **American Farrier's Association 54th Annual Convention** will be held March 16-20, 2026 in Little Rock, Arkansas. For more information, visit [www.americanfarriers.org/page/2026-convention-home](http://www.americanfarriers.org/page/2026-convention-home).

# Managing and Treating White Line Disease

By Austin Edens, CJF

AS SEEN IN THE  
NATURAL  
ANGLE  
VOL. 19 ISS. 4

White line disease (WLD) in horses is a hoof condition where anaerobic bacteria, fungi, or a combination of both invade and destroy the white line. With the deterioration of the white line, many problems arise such as; loss of structural integrity, abscessing, mechanical founder, and loss of sole depth.

## CAUSES:

White line disease (WLD) in horses is primarily caused by opportunistic fungi and bacteria that invade weakened or compromised areas of the hoof wall. These anaerobic microbes thrive in a moist cavity that is walled off from the outside world. As the WLD progresses, it creates its own larger habitat for more fungi and bacteria to colonize. I believe any horse is prone to WLD, but horses at highest risk are:

- Horses with seedy toe.
- Horses with stretched laminae from chronic laminitis.
- Poor conformation or balance.
- Wet-dry environmental cycles that weaken hoof integrity.
- Mechanical stress on hoof capsule from uneven weight-bearing.

## DISCOVERY AND DIAGNOSIS:

We have all worked on feet and felt a hollow spot, or investigated a small hole that revealed a large cavern. After discovering WLD, it can be tricky finding the margins of the cavity. WLD is like a wildfire. The leading edge of the WLD cavity is our main concern. If we fight the fire where it has already been, we aren't doing anything effective. We must extinguish the flames at the leading edge to stop the progression.

After discovering a WLD cavity, my first procedure is to investigate with a probe to see how large it is. If I am unsure and need further diagnostics, I will ask a veterinarian for x-rays with multiple views of the cavity. This can be helpful in formulating a strategy on debridement and treatment of the WLD.

## TREATMENT:

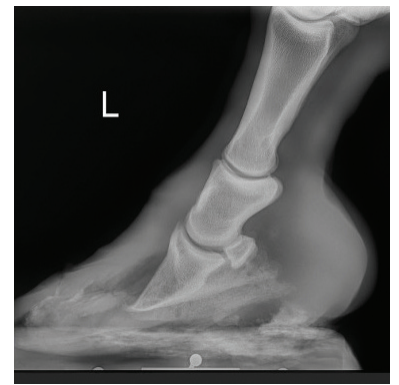**Small cavities** - Early detection of WLD cavities is key to prevention. If a cavity is small and its margins can be debrided from the solar surface, resection of the hoof wall may not be necessary. First, all flaky tissue should be removed, and if I am certain I have exposed all the leading edges, I may opt to pack the cavity with Allen's Copper Sulfate and FootPro CS Clay. The Allen's CS dissolves during the course of the shoeing cycle and leaches into the hoof wall, disinfecting the fungus and bacteria causing the WLD. The FootPro CS also has antimicrobial properties and holds the



A crack was discovered on a laminitic zebra at a local zoo. After the zebra was anesthetized, a wall resection done after x-rays revealed a large WLD cavity.



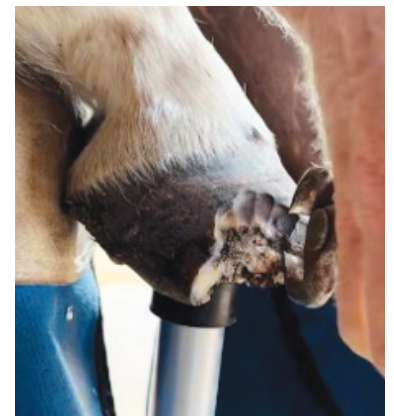
A chronic laminitic horse with a large WLD cavity prior to resection.



X-ray showing the extent of the cavity.



Half-round nippers used in resection and debridement of WLD cavity.



copper sulfate in place. This is a great option, because the hoof wall is left intact. This helps maintain a stronger hoof capsule and doesn't freak the horse owner out by doing a hoof-wall resection. This can be a risky procedure if the entire cavity is not debrided. If you are not 100% certain that all leading edges have been exposed, I would choose to do a hoof-wall resection.

**Larger cavities:** Treating WLD on larger cavities can be challenging. Resection of the hoof wall is necessary to expose the leading edges of the WLD. After the hoof wall removal, structural integrity of the hoof capsule is compromised. The best antiseptic for WLD is air. Exposing the anaerobic fungus and bacteria to air stops it in its tracks. However, if there is a hidden fissure that was missed during debridement, the WLD will continue on its destructive path. Using a topical antiseptic, such as Plexus CS Gel, on the leading edge helps ensure the effective treatment of the WLD. The Plexus CS Gel wicks into the wall and white line crevices to kill any problematic microbes.

**Topical treatments:** Antiseptics play a critical role in managing white line disease (WLD), particularly when used in conjunction with mechanical debridement. One of the most effective topicals for treating larger WLD cavities is Plexus CS Gel. After hoof wall resection has exposed the leading edge of the infection, Plexus CS Gel is applied directly to these areas. Its formulation allows it to wick deeply into the hoof wall and white line crevices, delivering antimicrobial action directly to where fungi and anaerobic bacteria are actively colonizing. This targeted delivery helps halt microbial progression, even in hard-to-reach fissures that might have been missed during debridement.



**Plexus CS Gel being applied to the leading edge of the WLD to disinfect any undiscovered fissures.**

**Whole-foot treatment:** treatment with Grand Circuit's White Lightning is an excellent option for both treating and preventing white line disease, especially in cases where multiple cavities or extensive infection are present. When used in a gas form under a hoof soak or boot, White Lightning penetrates deeply into every nook, cranny and crevice of the hoof capsule, reaching and disinfecting areas that may not be visible during routine trimming or debridement. This allows for comprehensive antimicrobial action throughout the hoof, targeting hidden pockets of infection and reducing the risk of recurrence. When the full hoof is compromised or when isolated treatment isn't practical, this method ensures nothing is missed.



**White Lightning mixed with vinegar works great to disinfect the entire foot.**



**A bag is used for the White Lightning/vinegar mixture for a thorough soak.**

**Hoof stabilization:** When a significant portion of the hoof capsule - sometimes as much as two-thirds - must be resected to fully expose and treat white line disease, mechanical stabilization becomes just as critical as antimicrobial therapy. With much of the hoof wall compromised or removed, the structural support that normally bears the horse's weight is greatly diminished. Fortunately, the frog can naturally support up to one-third of the horse's weight, and this load-bearing capacity becomes essential during recovery. A well-fitted heart bar shoe is ideal in these cases, as it transfers weight-bearing responsibility to the frog while simultaneously offloading stress from the damaged or absent hoof wall. This redistribution of load helps maintain hoof function, prevents further mechanical distortion, and supports the regeneration of a stronger, more balanced hoof capsule. In combination with precise trimming and casting or composite materials when needed, heart bars provide vital stability to the weakened hoof wall. While heart bar shoes offer excellent support for compromised hooves, they can present unique challenges - particularly when there is insufficient hoof wall remaining to securely anchor nails. In cases where large sections of the wall are missing due to resection, the farrier must



**A handmade heart bar shoe and Equi-Pak applied to a foot after a wall resection. The frog support and Equi-Pak aid in weight bearing after lost wall contact.**



**A preventer style medial branch helps ensure the shoe is not stepped on and pulled off.**

balance the need for stability with the limitations of available structure. Additionally, achieving a precise fit becomes more difficult when the hoof capsule is asymmetrical or incomplete. Without proper coverage, parts of the heart bar or flat shoe may protrude beyond the margin of the foot, increasing the risk of the horse stepping on the shoe. In these scenarios, supplemental stabilization with casting tape can be invaluable, helping to hold the shoe in place and protect both the foot and the hardware during the early stages of healing.

FootPro casting tape offers an excellent solution for stabilizing compromised hoof wall affected by white line disease. When applied as a rim cast, it reinforces the hoof capsule and provides the structural support typically offered by the hoof wall - crucial when a large portion has been resected. This not only helps maintain the integrity of the hoof but also gives the farrier a reliable platform to attach a shoe when traditional nailing isn't possible. An essential part of using casting tape in these cases is leaving an open window at the affected area. Sealing in infection is counterproductive; the exposed window allows for daily treatment and promotes air circulation, which aids in drying and disinfecting the diseased white line. This approach strikes a balance between mechanical support and therapeutic access.

FootPro Cast and Vettec Adhere are applied to stabilize the hoof capsule after resection. A window is cut into the WLD cavity for air exposure and the ability to treat affected area with Plexus CS Gel.

**Prevention:** Prevention of white line disease begins with vigilance during every trim or shoeing cycle. At each visit on WLD prone horses, the farrier should carefully inspect the white line for any signs of separation, cavities, or chalky, decaying material - early indicators of microbial invasion. When potential cavities are identified, they must be thoroughly debrided to remove compromised horn and expose clean, healthy tissue. I start by applying Plexus CS Gel directly into the cavity, allowing it to wick into the hoof wall and target hidden pathogens. After that, I pack the area with Allen's copper sulfate and FootPro CS clay. Whether applied under a shoe or to a bare foot, this combination offers both antimicrobial protection and a physical barrier, helping halt white line disease before a deeper or more extensive cavity can take hold. Consistent maintenance and early intervention are key to keeping the white line intact and the hoof strong. ■



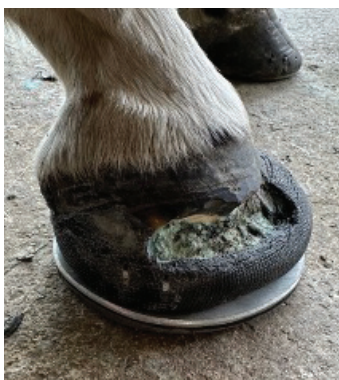Everything needed on the Hoofjack table for easy reach. FootPro Cast and Vettec Adhere to build a rim cast on the compromised hoof wall.



The resected hoof wall prior to casting.



FootPro Cast applied with FootPro DIM 20 in the caudal half of the foot to provide additional support.



Kerckhaert DF is nailed to FootPro Cast with an aluminum plate. FootPro DIM 20 is applied under the plate for additional solar support.



Packing area with FootPro CS Plus and Allen's Blue Powder for WLD prevention.

